

# RESPONSE OF TWENTY-SEVEN HORSES WITH LOWER LEG INJURIES TO HYDROTHERAPY

E.R. Hunt MVSc, PhD, G. Dip. Ed (Tert)

Veterinarian: Tiffany Marr, VMD

908-735-5300

HighPointEquine.com



## SUMMARY

The influence of hypertonic cold water (5-9°C) hydrotherapy on the response of 27 horses with various lower leg injuries is described. Fifteen horses with grade 2 or 3 superficial digital flexor tendon damage and four with suspensory ligament injury treated for 10 minutes three times a week responded with markedly improved ultrasonographic echogenicity and fiber realignment of injured tissues. All but two of these horses when placed back into training returned to compete successfully within six months without re-injury.

Two equestrian sports horses with traumatic contusion injury treated twice daily were able to compete successfully 72 hours after injury without supportive drug therapy. Responses of six individual horses with other leg conditions also responded to hydrotherapy faster than expected. The responses indicate hypertonic cold water spa therapy could be a valuable addition to therapeutic regimes with or without other therapies.

## INTRODUCTION

Hydrotherapy, or treatment in water, especially sea water or natural hydrotherapy water has long been used for the treatment of many health conditions. Both hot and cold baths have been used by human exercise physiologists and physiotherapists to treat muscle, joint and surgical injuries. Similar use has been made of sea water by some horse trainers in coastal locations and swimming of horses allows massage of joints and ligaments against the resistance of water.<sup>1</sup> However, some

local government regulations now preclude the swimming of horses at beaches, reducing the opportunity for this form of hydrotherapy other than in purpose-built facilities. Cold temperature effects (cryotherapy) of water immersion are less well tolerated in humans because of hypothermia and increases in blood pressure due to peripheral vasoconstriction<sup>2</sup>; however, local application of cryotherapy following injury without immersion in all species is well documented.

The standing of horses in running cold streams was historically recognized as beneficial for soreness after exercise. Running water maintains a constant temperature and provides mild massage which is beneficial with cold and has been a time-honored treatment for moderate contusion injuries in competition horses where anti-inflammatory drug therapy was not an option. For horses with flexor tendonitis or suspensory desmitis, cryotherapy with an optimal application time of 20 minutes is recommended.<sup>3</sup>

More recently, improvements in technology have increased the options for ultrasonographic diagnosis, treatment and monitoring responses to such treatment in lower leg tendonitis and desmitis,<sup>4,5</sup> with time frame from injury to successful competition suggested as just over a year.<sup>6</sup> Successful return to competition in racehorses, managed only by rest, has been described<sup>7</sup> as horses which competed in five or more races without recurrence of tendonitis but the report made no reference to time frame of return to racing.

The opportunity to examine the benefits of agitated immersion of the lower limbs of horses became available with the donation of a walk-in horse hydrotherapy in 1998 following earlier development of a trial unit in 1992. Anecdotal evidence from that trial unit indicated rapid healing of lower leg injuries, following treatment every other day.<sup>8</sup> The first cases treated at Orange responded quickly during

winter but more slowly during summer, and response was also found to be faster with the addition of salts to make the water hypertonic.

The responses of 27 subsequent clinical cases of new or recurring tendonitis, suspensory desmitis or lower limb injury to hydrotherapy and confinement prior to re-entry into training or continued competition is reported.

## MATERIALS AND METHODS

Cases were composed of fifteen bowed tendons, four suspensory ligaments, three cases of "jarring up" in training, one chronic fetlock synovitis, one horse two weeks' post surgery following arthroscopy of the metacarpophalangeal joint for bone chip removal, one which had been given antibiotic treatment for two weeks and bandaging for a penetrating wound of the digital flexor tendon sheath over the middle of the second phalanx, and two event horses with contusion injury following being cast in wooden rail yards and exhibiting extensive edema, severe stiffness and reluctance to move three days prior to competition.

At presentation horses were examined for obvious signs of lower limb injury, and ultrasound examination was performed if severe tendon or ligament damage was suspected. Two event horses injured three days before major competition were assessed only by palpation of edematous areas as clipping may have disadvantaged the horse in competition. For ultrasound examination, both limbs were clipped, washed, ultrasound coupling gel applied and a real-time sector scanner (Ausonics Opus1), with a 7.5 Mhz transducer with built-in stand-off used to produce transverse and longitudinal images initially at each of seven zones and then by measurement distal to the accessory carpal bone. Lesions at initial and follow-up scanning were determined by altered echogenicity<sup>8</sup> measured on transverse and longitudinal images and lesion length by distances distal to the accessory carpal bone. The ultrasonograms were recorded by a Mitsubishi thermal printer (Model PGO) and stored digitally after computer scanning. Following the line that tendon injuries must be treated individually as none are the same,<sup>4</sup> no control group was established and commercial clients wanted horses treated.

Horses had feet cleaned, legs hosed to remove dirt, and were fitted with a lightweight fecal collection harness. They were then walked into the spa bath chamber, doors closed and water fill commenced.

The hydrotherapy chamber has a water storage capacity of 2500 liters, maintained at 5 to 9°C, to which was added 20 g/l sodium chloride, 30 g/l magnesium sulphate. Chlorine was added daily to give a regular free chlorine value of 3 to 5% which together resulted in a conductivity quotient of 28.6 mS (cf. blood serum of 13.5 mS/cm/sec). Once water entry achieved a depth of 30 cm air agitation of water commenced. Water

entry was continued until the depth reached mid radius. Ten minutes following the start of air agitation, emptying of the hydrotherapy chamber commenced and water agitation ceased when the level was again at a depth of 30 cm. On emptying the spa the horse was led out, the fecal harness removed, and the legs hosed off. The horses were then confined to a 9m x 10m external yard, and not exercised until follow-up ultrasound indicated sufficient resolution of anechoic lesions. The hydrotherapy procedure was repeated three times a week Monday through Friday for a 3- or 4-week period for horses 1-20 ( Table 1) depending on severity and response, daily for horses 21-24 for two weeks, twice a week and on race days for horse 25 from week ten of training once fast work started and twice daily for horses 26 and 27 (the two event horses). Ultrasound examinations were performed every 7 to 14 days to evaluate healing according to the determinants of Genovese.<sup>4</sup> Each horse then commenced or continued training according to the decisions of the owner, sometimes based on programmed loading recommendations of the author, and responses to training were then obtained from owners /trainers by follow-up contact or race results. In some cases, further ultrasound examination was conducted prior to horses competing or after initial competition.

## RESULTS AND DISCUSSION

In the bowed tendon and suspensory groups of horses tendon or ligament injury was confirmed on ultrasound with lesions ranging from type 2 or type 3 for superficial digital flexor tendon<sup>8</sup> over 20% to 70% of the length of the tendon in Thoroughbreds and mostly discrete areas over 10% to 15% of the length of the mid portion of the tendon in Standardbreds. In each of the Standardbreds there had been a history of a fall or interference in running. The four suspensory lesions were all core lesions to either the medial or lateral branches of the ligament. There were an equal number of injuries on left and right sides.

The initial visual response to hydrotherapy was negligible until days 8-10 at which time general swelling was seen to be reduced. After seven days, changes could be seen on ultrasound examination. Resolution of core lesions had commenced and previously anechoic areas were reduced in size and had become partially echoic. Progressive changes over the next two to three weeks indicated commencement of healing of anechoic areas by hematoma resolution and decreased inflammatory infiltrate, independent of whether the injury was only three weeks old or up to four months old, together with a reduction in cross sectional area (CSA). Fiber alignment in longitudinal views demonstrated an improvement in parallel configuration after three or four weeks.

The use of cold in the initial stages of tendonitis and desmitis is well accepted; however, the continued use of cold with concurrent hypertonic water massage is now possible with the controlled temperature hydrotherapy. In

Table 1. Diagnostic features and outcome of hydrotherapy treatment of 25 horses with SDF tendonitis, DDF tendonitis, and suspensory desmitis or post arthroscopic surgery.

Horse No.	Breed, longitudinal length and description of major lesion and % cross sectional area (CSA) damage where applicable	Appearance after 3 weeks	Time to commencement training and performance
1	SB, repeat injury with enlargement of SDF and DDF, 2cm core lesion 22%	core lesion reduced with fiber realignment started, adhesions remained	Spell 1 w, 5 races 11 w- 15w, 2 wins, 2 places, 6w spell 2 races then injured other leg
2	SB, repeat injury, 4cm lesion SDF margin 10%	Lesion diminished and with fiber realignment	Spelled 8w, 5 races 20w -28w, 1 win, 3 places
3	TB, acute 4cm core lesion SDF medial margin 12%	realign of margins removal of anechoic areas	Spelled 12w, barrier trialled after 26w
4	TB, repeat injury, 5cm core lesion SDF 23%, new 2cm SDF lesion opposite leg 10%	core lesions reduced, reduction in total size and anechoic areas in both legs	Spelled 1w, raced 3 times 12 -15w, spelled 6w, won 2 race after 33w
5	SB, acute on chronic diffuse SDF swelling mid cannon with 17% increase in size, adhesions	SDF reduced to 12% larger better definition of tendon	Start training after 1 week, Raced at 16w placed
6	TB, 1.5cm core lesion lower medial branch suspensory 26%, extreme pain on palpation	core lesion reduced in size with increased echogenicity	Spelled 3w, 5 races 14-20w, 1 win; 3 races 26-30w, 1 win
7	SB, Acute 2cm and 4cm lesions both front legs after race fall with moderate distension of SDF tendon sheath 10% & 14% increase CSA	Swelling resolved with realignment of fibers	Spelled for 3m
8-15	TBs, 2cm -14cm type 3 lesions SDF with moderate distension tendon sheath 10-41 %	Swelling resolved with good alignment of fibers	5 raced in 18 weeks, 3 won, 1 reinjured, 1 retired
16	TB, 14cm type 3 core lesion SDF with diffuse area surrounding increased CSA by 56%	Swelling resolved with reduction in area	Raced in 18 weeks winning first start up a grade
17	TB, repeat injury after pin firing, 3cm core lesion to medial suspensory with 206% increase in CSA and 17% core lesion	ligament 21 % reduced, echogenicity increased	3/4 pace work at 12w another injury delayed return to races. Since placed
18-19	TB, Acute painful enlargement of distal end medial (18) and lateral (19) branch suspensory. Extensive disruption of fibers	Swelling diminished improved fibers and echogenicity	Spelled for 3m
20	TB, Arthroscopy lesion open and granulating, swollen, non weight bearing	Wound healed and swelling reduced, weight bearing	Spelled 2w, Raced at 14-19w, 2 wins
21-23	TB, slight inflammation and mild pain suspensory ligament both front legs on palpation	Swelling and pain diminished after 48h	Training continued, with one winning next start after 4d
24	TB, incision injury to DDF tendon sheath on pastern, closed with swelling proximally to mid cannon, pain over DDF causing lameness	Treated prior to spa with antibiotic 2 weeks. Swelling reduced, no lameness	Start training immediately. Successfully competed in dressage at 10w
25	TB, repeat fetlock synovitis last 3 race preparations. Joint injections of corticosteroid to keep racing. Chronic synovial swelling	Joint swelling reduced as fast work increased	Training continuous, Raced 5 times, placed

Abbreviations for Table 1: SDF, Superficial Digital Flexor; DDF, Deep Digital Flexor; TB, Thoroughbred; SB, Standardbred; CSA, Cross sectional area; d, day; w, week, m, month, h, hour

comparison with other treatments including tendon splitting, carpal check ligament desmotomy, intralesion injections of beta-aminopropionitrile (BAPN) or sodium hyaluronate, anti-inflammatory medication or support bandaging, hydrotherapy appears to offer an effective alternative with or without other therapy. The reported cases resolved much faster than expected with only one case in twelve with type 3 lesions re-injuring during early training. This is much lower than reported by Yovich<sup>4</sup> over an unreported time frame.

Horses 1 to 6 successfully returned to training within 12 weeks and four raced within 26 weeks, three of which won and placed in their first preparation with two winning in a second preparation after an eight-week spell. The response of horses 1 (Figs. 1a to 1c) and 2, which were given further rest after spa treatment, suggested future horses could return to

long, slow training earlier with successful outcomes. Horses 8 to 17 and horse 20 returned to walking exercise after the 3 or 4 weeks' treatment and completed full training over the next 12 to 18 weeks with a return to competition. Horse 15 (Figs. 2a and 2b) responded well to hydrotherapy treatment but had treatment terminated after three weeks when an extra week was recommended. In the case of horse 16 (Figs. 3a to 3c) and horse 17 (Figs. 4a to 4c) where injuries were adjudged more serious training was incorporated with hydrotherapy on fast work days. Horse 20 which had undergone arthroscopy of the metacarpophalangeal joint resulting in considerable joint swelling responded rapidly and confirmed the influence of cryotherapy in human arthroscopy cases without the use of other anti-inflammatories in pain reduction and improved weight bearing.<sup>9</sup>

Horses 21 to 23, the horses described by trainers as

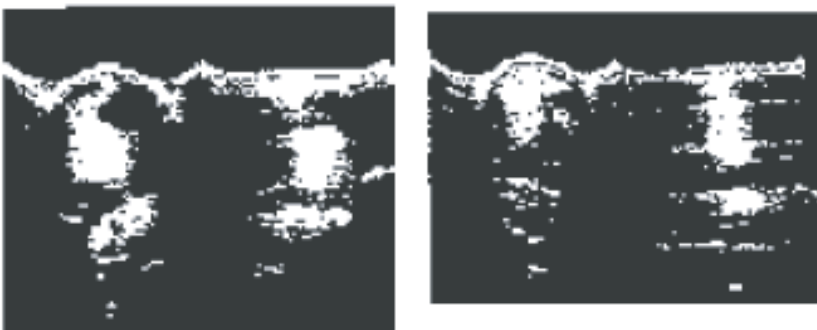


A. Diffuse lesion of SDF with accumulation of paratendinous fluid. Lesion extended from 15cm to 20cm below ACB.

B. Reduction in anechoic area and fluid with improved definition of SDF outline.

C. Almost normal appearance of SDF tendon.

Figure 1. (left) Transverse ultrasound scans from horse 1 of left front metacarpus 18cm below ACB taken: (A) 8 weeks after recurrence of injury during which time the horse was given yard rest and 1 week of oral phenylbutazone; (B) after 3 weeks of hydrotherapy treatment 3 times a week and; (C) after a further 9 months following nine race starts including some up 2 grades for 3 wins and 2 placings before redamaging SDF of opposite leg.



A. Type 3 core lesion involving 50% of medial margin of SDF in a tendon which had a 41 % increase in CSA and disruption of fiber pattern.

B. SDF tendon CSA reduced by 35% with improved echogenicity and fiber configuration. At this time a further week of hydrotherapy treatment was recommended prior to returning to exercise, but owners declined.

Figure 2. Transverse (on left where left is lateral) and longitudinal (on right where left is proximal) ultrasound images from horse 15 of right front metacarpus 18cm below ACB taken: (A) 4 weeks after initial injury during which time the horse was given yard rest; (B) after 3 weeks of hydrotherapy treatment 3 times a week.

“jarring up,” exhibited minor inflammation and soreness over middle of foreleg suspensory ligaments on both legs without any evidence of dorsometacarpal disease. Each had been described by experienced track riders as having a shorter, choppy stride than normal. Each continued training in association with hydrotherapy treatment. Each horse returned to normal striding within two days with horse 21 winning five days later.

Horses 7, 18 and 19 were spelled by owners for three months and horse 20 for 2 weeks before return to training. Horse 19 (Figs. 5a to 5c) was also scanned at the end of the three months’ spell prior to returning to training and the ligament was considerably improved with a return to normal consistency on palpation.


In all cases reduction in paratendinous and tendinous fluid and any hematoma appeared to enhance the healing process. In one case only the injury reportedly recurred after six weeks of training, and horse 1 had two preparations with 3 wins, two at a higher grade, before a severe superficial digital flexor lesion developed in the other leg. One eight

year- old TB with a type 3 lesion was retired after ten weeks of training to hacking rather than risk further injury. All other horses have returned to competition.


In horses 25 and 26 with skin contusion and edema but without apparent tendon or ligament damage edema and pain were alleviated in part immediately. Each horse passed a compulsory competition veterinary examination and competed successfully without lameness 72 hours after injury. This demonstrated the potential value for resolution of contusion injuries in competition horses. The analgesic effect from constant cold and reduction of edematous fluid allowed both horses to compete successfully drug free. During the development of the spa the improved response of injuries to controlled cold and added salt was evidenced. Agitated cold water is denser and contains a very high dissolved oxygen content by comparison with warmer motionless water and it is, therefore, believed that the combined influence of hypertonicity, massage effect of agitation, cold, and the effect of pressure from the depth of water,<sup>11</sup> in combination, aids in fluid dispersal and minor



A. Type 3 core lesion of SDF occupying 38% of the CSA in tendon which was 56% larger than the opposite leg at the same level. The lesion extended from 12cm to 24cm distal to ACB.

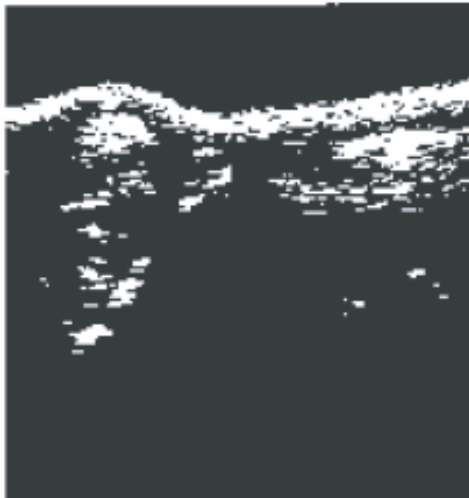


B. Core lesion almost diminished with 39% reduction in tendon CSA.



C. Tendon showing almost normal configuration.

Figure 3. (above) Transverse (on left where left is lateral) and longitudinal (on right where left is proximal) ultrasound scans from horse 16 of right front metacarpus 15cm below ACB taken: (A) 6 weeks after initial injury during which time the horse was given stall rest with support bandaging; (B) after 4 weeks of cold spa treatment 3 times a week and; (C) after a further 5 months following three race starts up a grade for a first and second and at group level for a near placing.



A. Core lesion (17%) on posterior surface with extensive fluid below a thickened cutis. CSA of the ligament was 206% larger than the medial ligament on opposite leg.



B. Reduction in fluid and improved echogenicity of core lesion with reduction in CSA by 21%.



C. Improved structure of ligament with 29 reduction in CSA compared with B Ligament remains 74% larger in CSA than opposite leg. This continued to decrease over time.

Figure 4. Transverse ultrasound scans from horse 17 of right front medial branch of the suspensory ligament 22cm distal to ACB taken: (A) 5 weeks after re-injury of the ligament. The horse had previously been pin fired over the whole of the metacarpal region and was given yard rest; (B) after 3 weeks of cold spa treatment 3 times a week and; (C) after a further 4 weeks of slow walking and trotting with continued hydrotherapy treatment.



A. Diffuse lesion with loss of fiber integrity and fluid disruption. Ligament has a 122% increase in CSA compared with lateral ligament on right leg with 43% area involvement and extensive echogenic material medial to ligament.

B. CSA slightly reduced (5%) but reduced fiber disruption and improved longitudinal alignment.

C. Ligament integrity almost returned with 24% CSA reduction.

Figure 5. Transverse (on left where left is posterior) and longitudinal (on right where left is proximal) ultrasound images from horse 19 of left lateral branch of the suspensory ligament 26cm below ACB taken: (A) 4 weeks after initial injury during which time the horse was given yard rest; (B) after 4 weeks of cold spa treatment 3 times a week and (C) after a further 12 weeks of paddock rest.

skin and subcutaneous tissue wound repair more than any single component. In varying grades of superficial flexor tendon injury or suspensory ligament damage cold spa bath hydrotherapy for three or four weeks resolved the fluid component of the injury which together with a slow progressive exercise loading over 16 to 18 weeks allowed most racehorses to return to successful racing within six to eight months. In the more severe cases the combination of spa therapy during the training program is believed to have aided recovery and would be the preferred management approach. The response of cases with physical or trauma induced inflammation indicated potential value of hydrotherapy in any cases involving lower limb inflammation especially where alternate drug therapy was not an option.

#### FOOTNOTES

aEquine Therapeutic Spas Pty Ltd, PO Box 627, St Marys NSW 1790 Australia

#### REFERENCES

1. Auer JA: Physical therapy and rehabilitation. In: Jones WE, Equine Sports Medicine. Malvern PA: Lea and Febiger, 1989:249-251.
2. Michlovitz SL: editor. Thermal Agents in Rehabilitation. Philadelphia: FA Davis, 1990:63-67.
3. Watkins JP: Treatment principles of tendon disorders. In: Auer JA, editor. Equine Surgery. Philadelphia: WB Saunders, 1992:916-924.
4. Genovese RL: Treatment of superficial digital tendonitis-An opinion. In: Rantanen NW, McKinnon AO. Equine diagnostic ultrasonograph. Baltimore, Williams and Wilkins, 1998:543-580.
5. Reef VB: Equine Diagnostic Ultrasound. Philadelphia:WB

Saunders, 1998:39-186.

6. Reef VB: In: Round table discussion Equine Tendonitis Part 3. Equine Practice 1999;21:14-18.

7. Yovich JV, Sawdon H, Booth T, Robertson ID: Correlation of ultrasonographic findings and long term outcomes in racehorses with superficial digital flexor tendon injury. Aust Equine Veterinarian 1995;13(4):89-92.

8. Genovese RL, Rantanen NW: The superficial digital tendon. In: Rantanen NW and McKinnon AO, Equine diagnostic ultrasonography. Baltimore, Williams and Wilkins, 1998:289-398.

9. Lessard LA, Scudds RA, Amendola A, Vaz MD: The efficacy of cryotherapy following arthroscopic knee surgery. J Orth Spts Phys Ther 1977;26:14-22.

10. Griffiths JB, Steel CM, Symons TJ, Yovich JV: Improving the predictability of performance by prerace detection of dorsal metacarpal disease in thoroughbred racehorses. Aust vet J 2000;78:466-467.

11. Hall J, Bisson D, O'Hare P: The physiology of immersion. Physiology 1990;76:517-521.